

## UNDERSTANDING ANATOMY:

# Drawing the Leg

by Ephraim Rubenstein

Our legs are the pillars upon which we stand. They afford us independent mobility, and our ability to walk, run, and jump is synonymous with our sense of personal autonomy. To use legs expressively in our work, we have to be able to draw them in a multitude of positions and from every possible angle. In order to do this, we must first understand the structure of the leg, both inside and out.

### Form and Function

The body is a complex series of levers and pulleys. If you can think about what each muscle is trying to do, you will understand its form more clearly. Perhaps the major functional principle in drawing the leg is that the movement of any part—the thigh, lower leg, or foot—is controlled by the part preceding it anatomically. Therefore, the muscles of the hip and pelvis control the thigh, the muscles of the thigh move the lower leg, and the muscles of the lower leg control the ankle and foot.

### Bones and Joints

The leg is divided into two parts: the thigh and the lower leg. The thigh has only one bone, the *femur*, while the lower leg has two, the *tibia* and the *fibula*. Thrown in for good measure is a fourth, small, triangular bone, the *patella*, which protects the knee joint like a small shield.

The femur is the longest bone in the body. It is a fifth as long as the tibia and fibula, which means the distance from the hip to the knee is greater than from the knee to the ankle. Contrary to expectation, the femur does not follow the general axis of the thigh, but slants obliquely downward and inward.

The leg has three major joints: the hip, knee, and ankle, and all offer varying degrees of movement. The hip is a

ball-and-socket joint that affords extensive movement in three general directions: *flexion* and *extension*; inward and outward rotation; and lateral movement. Moving the legs together laterally is known as *adduction* and apart as *abduction*. This great degree of flexibility allows us to execute maneuvers such as grand pliés in ballet and full splits in gymnastics.

The knee is a more limited hinge joint, and the articulation between the femur and the tibia allows only for flexion and extension. The small triangular bone of the patella, the major landmark of the knee area, rides in a notch at the base of the femur and is attached by strong tendons on top and bottom. It functions like a doorstep to prevent the leg from hyperextending forward.

Finally, the ankle is made up of seven small bones arranged roughly in two rows. They are bound together in a shallow arch, and their articulation with the tibia and fibula allows for a good deal of flexion and extension and a lesser amount of lateral movement and rotation.

### Major Masses

The thigh can be divided into three major muscle masses: the *quadriceps* in front; the *adductor* group high up on the inside of the thigh; and the *biceps*, *semimembranosus*, and *semitendinosus* in the back.

The quadriceps, named for their four distinct heads, act to extend the lower leg and to flex the thigh against the pelvis. All four fleshy bodies join in a common tendon that crosses the patella and inserts into the upper end of the tibia.

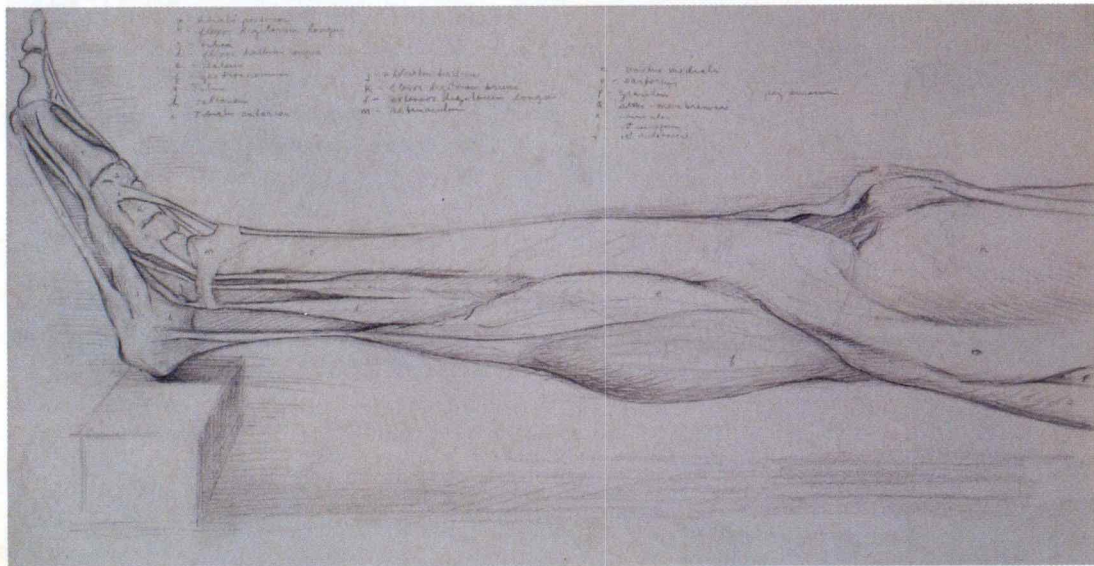
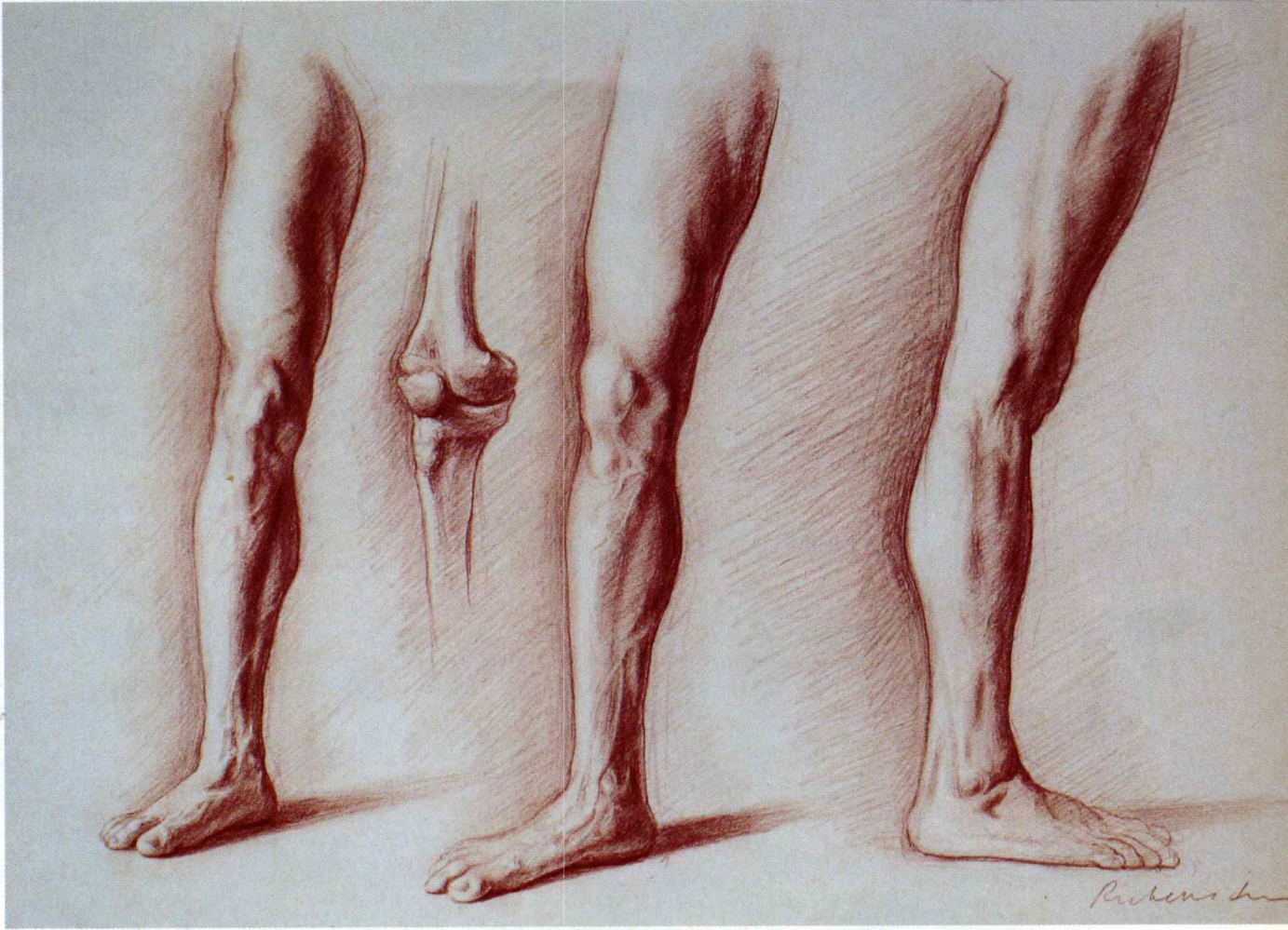
The adductor group consists of several muscles that join themselves into a united shape that is rarely subdivided. These muscles draw the leg inward toward the central axis of the body.

BELOW

### Three Studies of a Right Leg

2006, red chalk, 13 x 20. All artwork this article collection the artist unless otherwise indicated.

This study shows the major masses of the same leg from three different angles. Notice how the contour of the knee or calf muscle, for instance, changes as the leg is rotated. Subtle changes in rotation will greatly affect the reading of the contour.

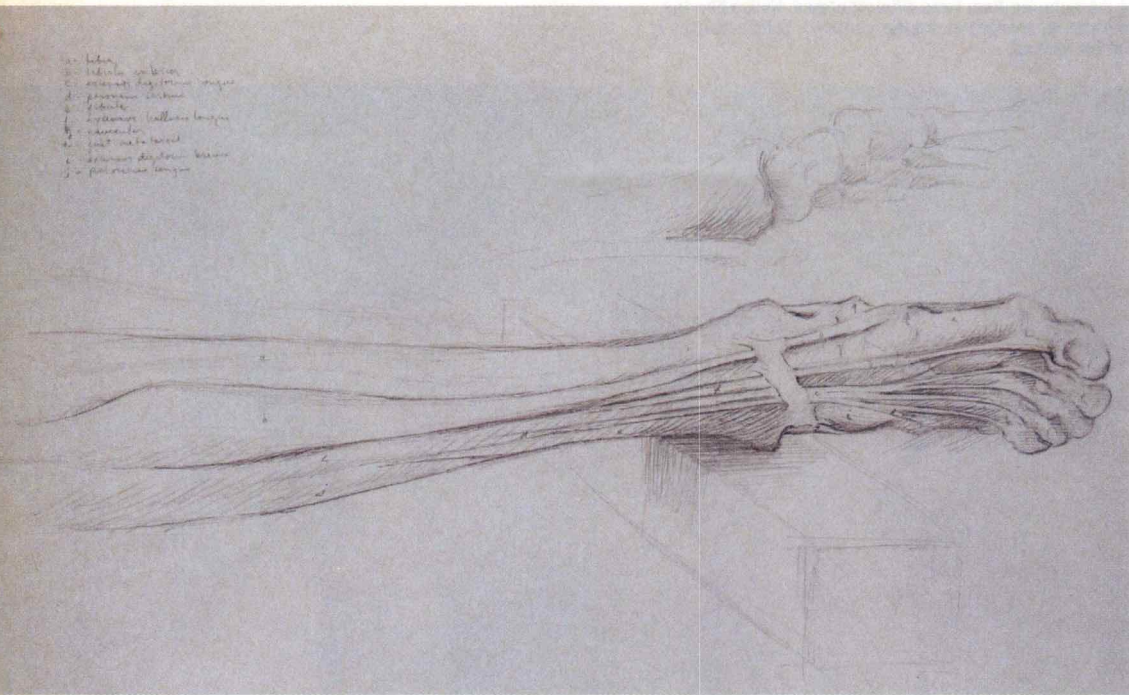


LEFT

### Dissection Study of the Leg II

1982, graphite, 11 x 15.

My dissection work with Salvatore Montano over a four-year period was an experience that changed my life. Nowhere is "the body as machine" (as an elaborate system of levers and pulleys) more apparent than when examining a cadaver. The long tendons of the lower leg are particularly complicated, and this dissection required the greatest delicacy.



**LEFT**  
**Dissection Study of the Leg I**

1982, graphite, 11 x 15.

**BELOW**

**Anna's Legs**

2004, red chalk, 19 x 26.

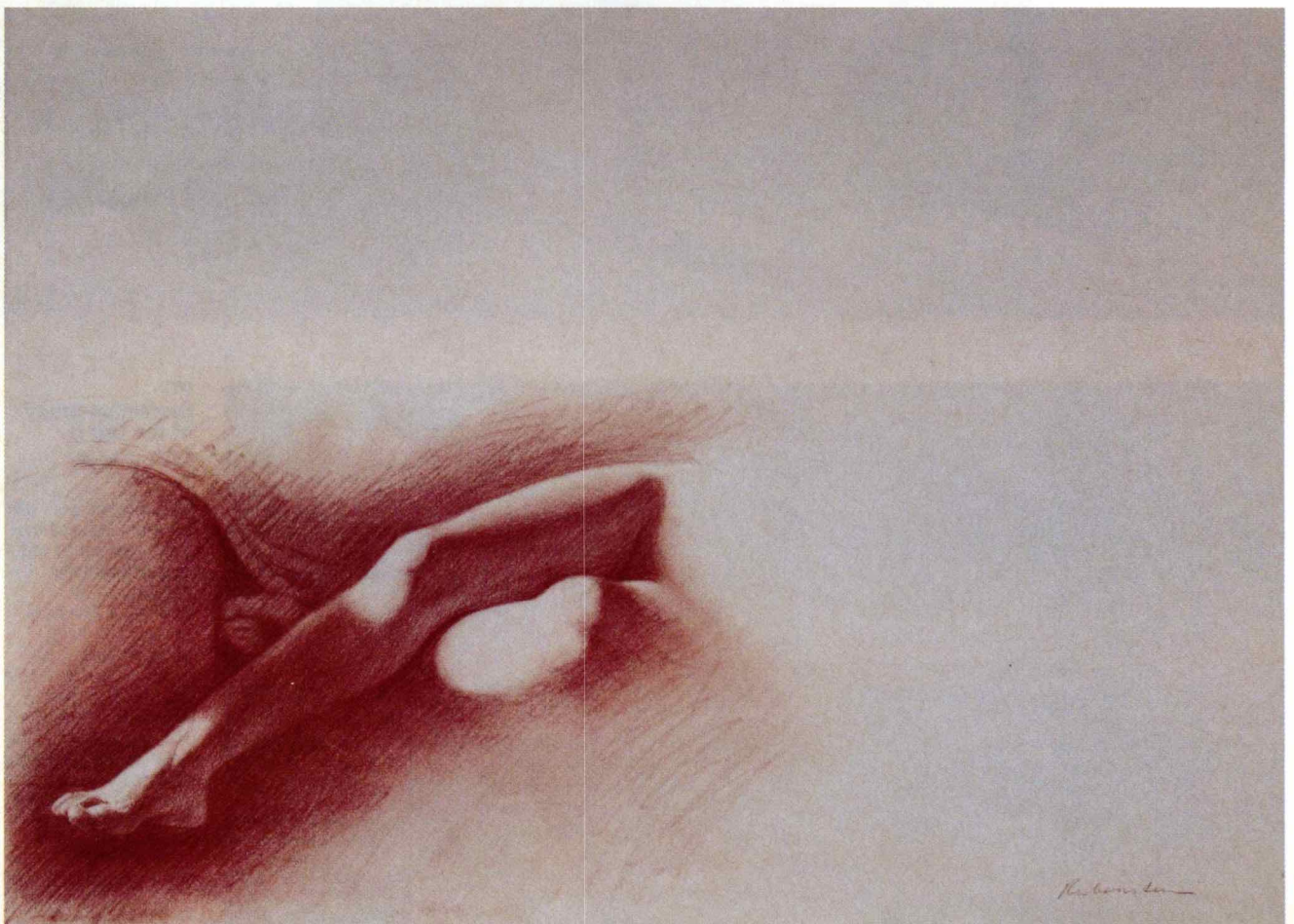The goal of understanding artistic anatomy is so that you can use the body for your own expressive purposes. The pattern of light and dark on the model's legs contained so much mystery, I decided to let them speak for the whole figure.

**OPPOSITE PAGE**

**Sarah IX**

2004, red chalk, 19 x 26.  
 Collection Scott Noel.

The undulating movement of the leg is particularly beautiful as it tapers from thigh to ankle. In this drawing, I played this beautiful rhythm off against the intricate folds of the drapery, themselves incredibly sensuous.





The back of the thigh consists of two pairs of muscles that begin together at the top, but whose tendons branch off in opposite directions below, forming the distinctive V-shaped hollow at the back of the knee. These visually prominent tendons are commonly called the hamstrings. The major function of these muscles is to flex the lower leg.

In addition, there are two long muscles that act as landmarks to divide the three major masses. The *sartorius* and the *tensor fasciae latae* both originate on the outside of the pelvis but immediately separate as they descend. The *tensor fasciae latae* has a prominent egg shape when flexed but flattens out as it drops straight down to form part of the *illiotibial band*. The *sartorius*, on the other hand, moves obliquely across the thigh descending to the inside of the knee and is the longest muscle in the body.

While the thigh is extremely muscular, the lower leg is relatively boney. The crest of the tibia, the head of the fibula, and both the *lateral malleolus* and *medial malleolus* are

visible right under the surface of the skin. Most of the muscles of the lower leg are relatively flat with long tendons. The *gastrocnemius*, however, is a large muscle on the back of the leg with two distinct heads, the lateral being higher than the medial. Along with the *soleus* and *plantaris*, they make up the calf muscle group, which acts as a powerful extensor of the foot. These muscles taper into the Achilles tendon, which attaches the leg to the heel of the foot.

The other muscles of the lower leg can be grouped as either extensors or flexors of the ankle and foot, with the flexors situated to the front and lateral side of the crest of the tibia, and the extensors on the medial and posterior side.

### Tapering

Like the arm, the leg narrows as it descends, tapering supplely from the thigh to the ankle. But in addition, the thigh and the lower leg each taper individually from top to bottom, setting up an undulating rhythm of swelling and narrowing that is incredibly beautiful. ❖